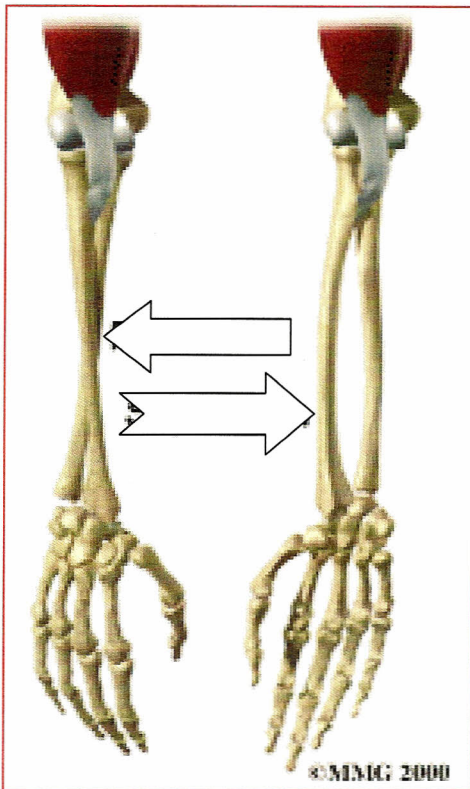

LABEL
 EACH
 PICTURE
 WITH THE
 CORRECT
 MOTION!

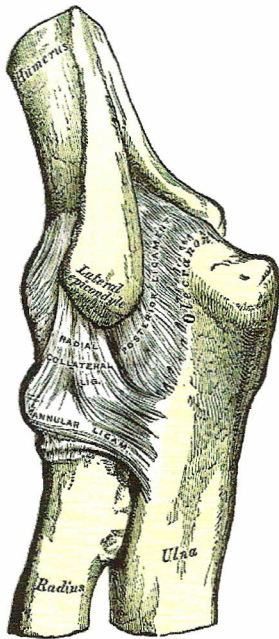
Which Joint is moving in the above picture?

What two motions are occurring?

What muscles do each motion?

Do any of the muscles originate on the medial epicondyle? If so which one?

Do any of the muscles originate on the lateral epicondyle? If so which one?



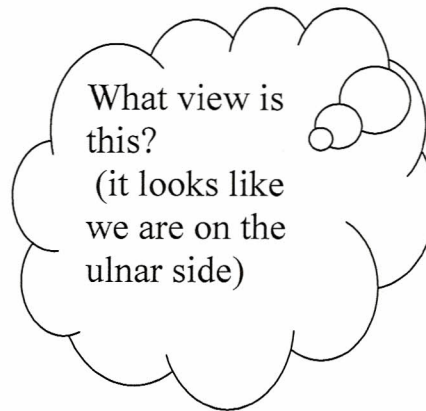
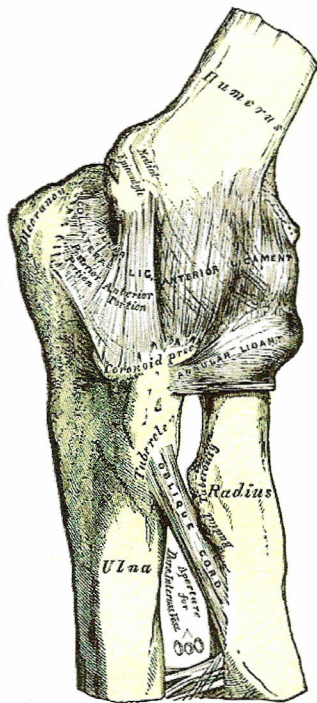
What view
is this?

Which ligament is shown in the picture?

What are the two names it can have?

How is this ligament injured?

What kind of force is it called?



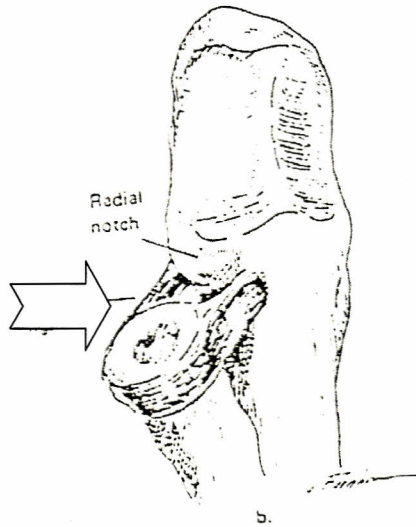
What are the two names for this ligament?

What two bones are connected?

There are two main ways this ligament is injured (ACUTE AND CHRONIC)
Describe each

Acute (name the type of force)

Chronic



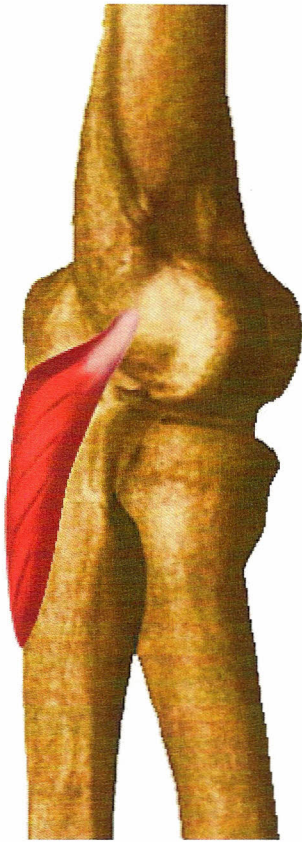
Identify the ligament

What does this ligament do?

(EXTRA CREDIT) I mentioned this ligament is very rarely injured. It is sometimes injured in toddlers and young children. What is the nickname for this injury?

What limits hyperextension in the elbow (bony structures?)

What limits flexion of the elbow (identify bony structures and soft tissue structures)

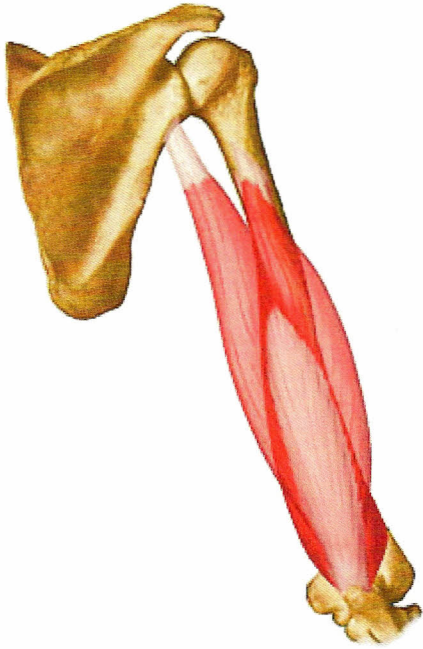


NAME THE MUCLE

What is the primary function of this muscle?

What muscle does it assist?

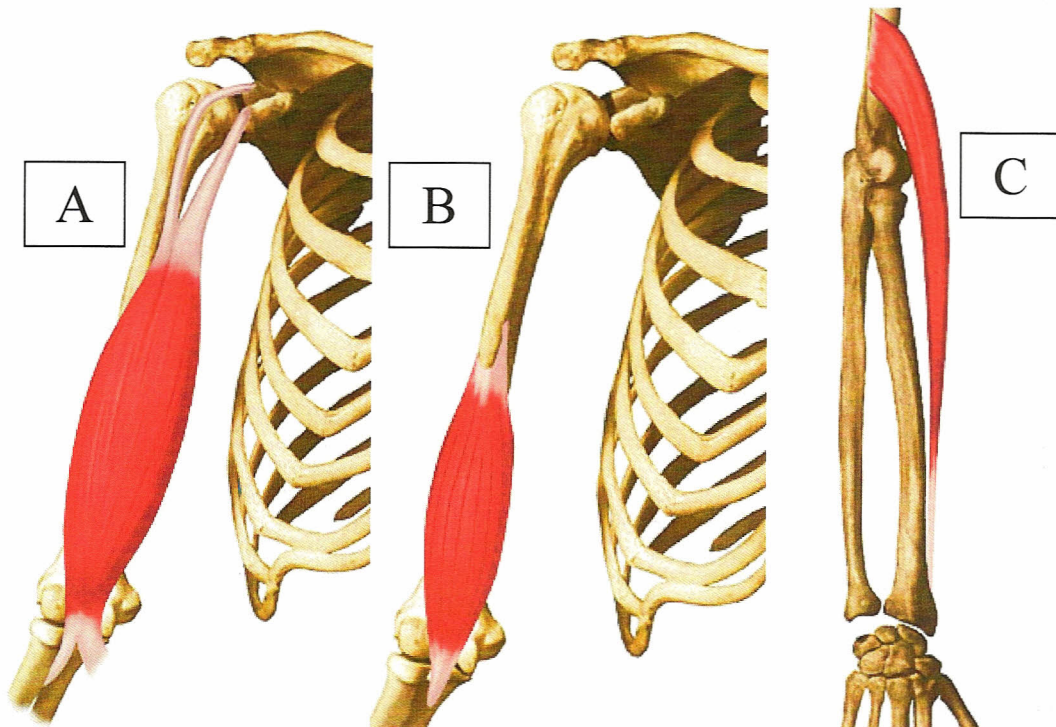
Identify its Origin and Insertion (LOOK AT THE PICTURE!)



What is the name of this muscle?

What is its Function?

What bony Landmark does it insert on?



PICTURE "A"

Name the muscle

Name its two functions?

Where does this muscle insert?

What forearm position does it function?

PICTURE "B"

Name the muscle

Name its functions?

Where does this muscle insert?

What forearm position does it function?

Picture "C"

Name the muscle

Name its function

Identify the forearm picture?

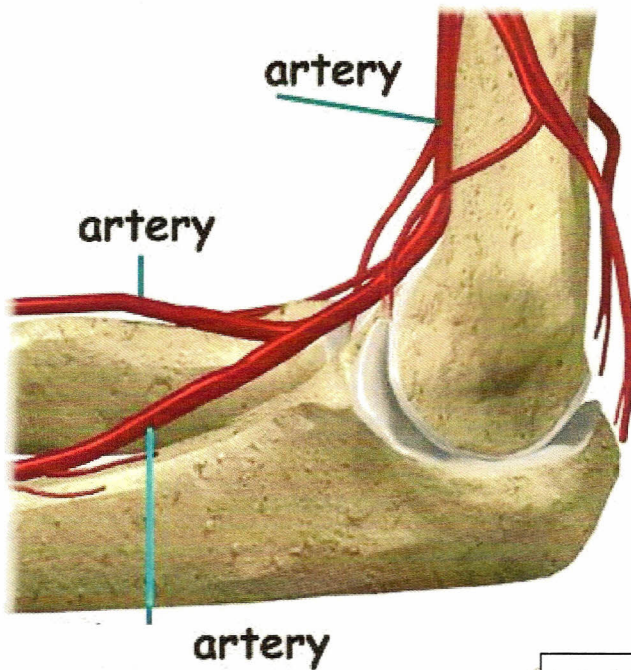
IDENTIFY 6 MUSCLES THAT ORIGINATE AT THE MEDIAL EPICONDYLE	IDENTIFY 6 MUSCLES THAT ORIGINATE AT THE LATERAL EPICONDYLE

What are the primary functions of the muscles that originate at the medial epicondyle?

What is the term for tendonitis of the medial epicondyle?

What are the primary functions of the muscles that originate at the lateral epicondyle?

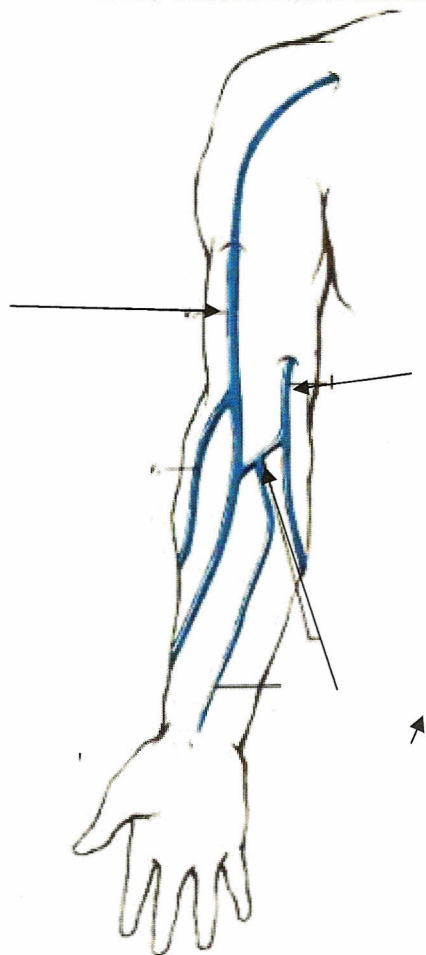
What is the term for tendonitis of the lateral epicondyle?



Label each artery.

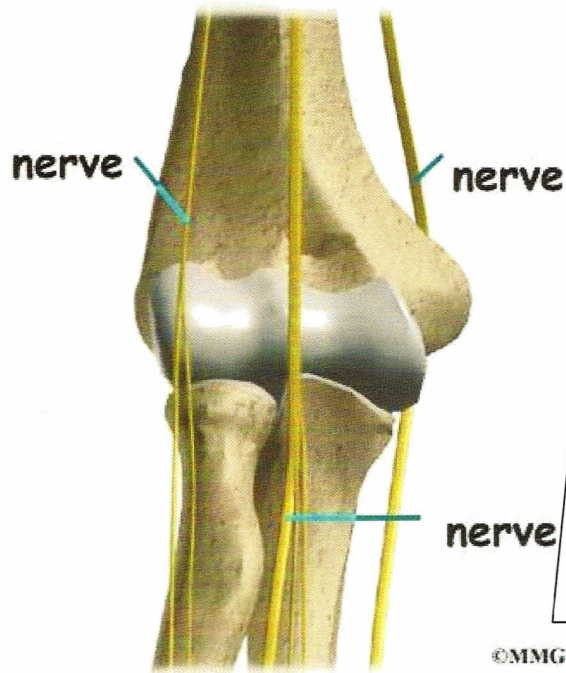
Which one is used to take your blood pressure?

Which one is used to check the pulse in your wrist?



Label the three veins.

Which one is commonly used to draw blood?



Label each nerve.

Identify the parts of the hand that each nerve supplies sensory and motor function to.